



HAL
open science

Depression after temporal muscle flap: A systematic review of the literature

J. Laloze, J. Brie, B. Chaput, J. Usseglio

► To cite this version:

J. Laloze, J. Brie, B. Chaput, J. Usseglio. Depression after temporal muscle flap: A systematic review of the literature. *Journal of Cranio-Maxillofacial Surgery*, 2019, 47 (7), pp.1104-1109. 10.1016/j.jcms.2019.03.031 . hal-03276873

HAL Id: hal-03276873

<https://unilim.hal.science/hal-03276873>

Submitted on 25 Oct 2021

HAL is a multi-disciplinary open access archive for the deposit and dissemination of scientific research documents, whether they are published or not. The documents may come from teaching and research institutions in France or abroad, or from public or private research centers.

L'archive ouverte pluridisciplinaire **HAL**, est destinée au dépôt et à la diffusion de documents scientifiques de niveau recherche, publiés ou non, émanant des établissements d'enseignement et de recherche français ou étrangers, des laboratoires publics ou privés.



Distributed under a Creative Commons Attribution - NonCommercial 4.0 International License

Correction of depression after temporal muscle flap: a systematic review of the literature

Authors name and affiliations

LALOZE J. MD

- Department of maxillo-facial and reconstructive surgery and stomatology, Dupuytren University Hospital, 2, avenue Martin Luther King, 87042 LIMOGES, cedex, France
- STROMALab, Toulouse University, EFS, ENVT, INSERM U1031
- jeromelaloz@etu.unilim.fr

CHAPUT B. MD, PhD

- Department of plastic, reconstructive and aesthetic surgery, Rangueil University Hospital, Plastic and Reconstructive Surgery Department, 1, avenue Jean Poulhès, Toulouse, FR 31059
- STROMALab, Toulouse University, EFS, ENVT, INSERM U1031
- chaput.b@chu-toulouse.fr

Depression after temporal muscle flap: a systematic review of the literature

Summary

Background

There are several ways to fill the depression created after temporal muscle flap. Historically, many methods have been described but biomaterials are increasingly used for this indication. We conducted a systematic review of the literature on the use of biomaterials to fill this depression.

Methods

The databases MEDLINE (via PubMed), Cochrane Library, EBSCO, Web of Sciences and Embase were searched for clinical trial reports, case series, case reports and cohort studies from 1991 to 2015. We conducted a systematic review of the use and efficacy of different biomaterials. Patient satisfaction was systematically researched.

Results

We identified 11 articles (196 patients) which were included in the systematic review. The biomaterials used are polymethyl methacrylate (PMMA), polyethylene (PE), lipofilling, Titanium (Ti) and Mersilene Mesh (MM). Complications occurred only with PMMA and MM. Patient satisfaction was rather good in all the studies.

Conclusion

There is no evidence of the superiority of one biomaterial over another as there was a lack of high quality studies. More randomized and controlled studies are required to draw conclusions on the matter.

Keywords

Literature review, temporal muscle flap, reconstruction, temporal depression, biomaterial

Introduction

The temporal muscle flap has been used successfully as a pedicled flap in craniofacial surgery for over a century (Shagets, et al., 1986; Koranda et al., 1987). The capacity to cover large congenital, trauma, skeletal or facial surgery defects has been proven in many studies (Habel and Hensher 1986; Colmenero, 1991; Demas and Sotereanos, 1989; van der Wal and Mulder, 1992; Bradley and Brockbank, 1981). The temporalis muscle is commonly used as a pedicled flap (Spanio di Spilimbergo, 2017) primarily to fill cavities within a radius of about 8 cm from the coronoid process (Shagets et al., 1986): exenterated orbit (passing through the outer orbital wall) (Adenis, 1998; Gola, 1989; Menon, 2003), filling of the cheek or upper maxilla (orbital floor, nasal fossa, ipsilateral palate (Koranda et al., 1987; Demas and Sotereanos, 1989; van der Wal and Mulder, 1992)). It is used to treat temporomandibular ankylosis (Su-Gwan, 2001; Majumdar and Bainton, 2004). Temporalis muscle grafts are also used as a cover. Other applications are possible in facial paralysis, where parts of the temporal muscle can be transferred to resuscitate mouth-corner or palpebral occlusion. This technique applied for this indication is called lengthening temporalis myoplasty.

Temporal depression is a common consequence of temporalis muscle flap (TMF). This defect is characterized by a concavity in the soft tissue contour of the temporal region and is associated with marked elevation of the lateral orbital rim and zygomatic arch. This defect is not mentioned by most authors, was dismissed as minimal by Koranda et al. (1987) (Koranda et al., 1987) and described as being smoothed out by scarring after several months by Huttenbrink (1989) (Huttenbrink, 1989). For several years, no surgical procedure was used to reconstruct this defect. Instead, it was camouflaged via hair styling which was obviously problematic in bald men. Habel and Hensher (1986) acknowledged the problem and suggested using only the posterior

part of the muscle if possible, to reduce the cosmetic defect (Mandlik, 2015). However, Tan et al. demonstrated that the remaining anterior part was not sufficient to fill the depression (Tan et al., 2007). Bradley et al. (1988) suggested two solutions. The first was to avoid replacing the resected arch so that the change in contour was less abrupt, and the second was to use a free fat graft from the buttock.

Other authors transferred the buccal fat pad, bone grafts and other autologous materials. But, over time, these materials tend to be reabsorbed, especially after radiation, with poor long-term cosmetic results.

This marked the emergence of the use of biomaterials (BM). The most suitable material must be biocompatible, tissue-friendly, stable, easily malleable, custom-made and radiation-friendly.

Several biomaterials are currently used to fill temporal depressions. Porous high-density polyethylene implants (PHDPE or PE) or polymethyl methacrylate (PMMA) can be used either alone or in combination with residual muscle in the temporal fossa, and represent the most widely used substances in such reconstructions at present (Mandlik, 2015; Baj, 2009). Studies have confirmed the safety and clinical effectiveness of these materials in the restoration of temporal defects.

There are other materials and techniques for this indication, such as titanium implants (TI) (Hatamleh, 2013), Mersilene mesh (MM) (Atherton et al., 2010) and autologous fat transplantation (lipofilling) (Cervelli, 2014).

Evidently, the range of available techniques is wide and heterogeneous. However, no

comparative study was found that assessed the superiority of one or the other. Consequently, we decided to conduct a systematic review of articles concerning the use of biomaterials to reconstruct defects after temporalis muscle flap. We tried to identify the ideal biomaterial to repair soft tissue hollowing.

Search Strategy

Two independent reviewers conducted a systematic review of related articles published between 1991 and 2015 in the MEDLINE (via PubMed), Cochrane Library, EBSCO, Web of Science and Scopus databases. This systematic review respected the PRISMA standard. The following keywords were used for the search: “temporalis muscle flap donor site” or “temporalis muscle flap morbidity” or “temporalis muscle flap complication” or “temporalis muscle flap hollowing” in combination with “reconstruction” or “rehabilitation” or “management” or “restoration”. Gray literature was also searched.

Study selection

Article selection was based on an initial screening of titles and abstracts and was followed by screening of full texts. The eligibility criteria for studies were 1) Reconstruction of a defect with a biomaterial following temporalis muscle flap; 2) Evaluation of the cosmetic results at least by the patient; 3) A minimum follow-up of 6 months; 4) Articles written in English. Exclusion criteria were 1) Animal studies or preclinical studies or reviews; 2)

TMF defect non-reconstructed with a BM and 3) Combined treatment (a combination of two BMs, or a combination of a BM with any other technique).

Data collection process and quality assessment

Data were extracted by two independent reviewers (J. L. and J. U.) who used a standard data collection form. Each study was assessed for study quality and level of evidence according to the Oxford Center for Evidence-Based Medicine 2011 guidelines (Howick et al., 2011). Two reviewers independently scored the study quality.

Literature search (Figure 1)

Database searches using predefined keywords yielded 7,386 articles. After adding articles from reference lists and removing duplicates, 543 potential articles were screened by reading the titles. From these, the abstracts of 46 articles were screened. The full texts of 24 articles were then screened. 11 articles fit the inclusion and exclusion criteria, and were included in the systematic review.

Characteristics of studies that were included (Table 1)

The characteristics of the 11 articles (196 patients) in the systematic review are in Tables 1 and 2. In four articles, PMMA was used (Mandlik, 2015; Falconer and Phillips, 1991; Cheung et al., 1994; Wright, 2006), in another 4 articles PE was used (Baj, 2009; Worley and Strauss, 1994; Rapidis and Day, 2006; Lacey and Antonyshyn, 1993), in 1 article lipofilling was used (Cervelli, 2014), in 1 article Titanium was used (Hatamleh, 2013) and in 1 article Mersilene Mesh was used (Atherton et al., 2010).

102 patients benefitted from the use of PMMA, 38 from PE prosthesis, 45 from lipofilling, 1 from a titanium prosthesis and 10 from Mersilene Mesh.

The average ages of the different BM groups are similar: 61.03 years for the PMMA group, 47.55 for the PE group, 52.8 for the lipofilling group, 54 for the titanium group and 40.1 for the Mersilene Mesh group. The average age for all patients in this review is 51.1 years.

With regards to study quality, 10 are level 4 (Mandlik, 2015; Baj, 2009; Hatamleh, 2013; Atherton et al., 2010; Falconer and Phillips, 1991; Cheung et al., 1994; Wright, 2006; Worley and Strauss, 1994; Rapidis and Day, 2006; Lacey and Antonyshyn, 1993) and 1 is level 3 (Cervelli, 2014) (Table 2).

The mean follow-up for this review was 38,72 months (61,1 for PMMA group, 26,22 for PE group, 15,9 for Mersilene Mesh, 22 for lipofilling). The follow-up was not communicated for the article with titanium.

Efficacy

Satisfaction was good for all the studies.

Safety

In terms of safety, we recorded a total of 6 complications for 196 patients (3.06%). There were 2 infections (1.02%). One occurred in the study by Wright et al. with PMMA (1.96% of the 102 patients) and the other in the study by Atherton et al. with the use of Mersilene Mesh (10% of the 10 patients). Two persistent depressions at the donor site which required re-intervention within 21 months were found in the Cheung et al. article (1.96% of PMMA patients). Two other complications occurred in the Mandlik et al. study with the use of PMMA, including 1 seroma (0.98% of patients) and one wound dehiscence (0.98% of patients). Finally, 2 implants were removed as a result of infection and a dehiscence wound (Mandlik, 2015; Wright, 2006).

Discussion

Temporal muscle flap is a widely used flap in the reconstruction of the orofacial sphere. Whether pedicled or free, whole or duplicated, there is always a purely aesthetic defect at the donor site.

For several decades now, there has been a growing interest in repairing this depression, particularly with biomaterials. However, none has yet been clearly proven to be superior over another, which leads to excessive variability in patient care. It is important to know whether

some biomaterials are more effective than others in order to generalize their use among maxillofacial surgeons. Therefore, our aim was to reference all the articles that dealt with donor site filling of a temporal muscle flap with a biomaterial, through a review of the literature.

The first step of our work was to identify what is a biomaterial. For example, it is not clearly expressed in the literature if lipofilling is a biomaterial. Many consider a biomaterial as any substance that has been engineered to interact with biological systems for a medical purpose, either a therapeutic (treat, augment, repair or replace a tissue function of the body) or a diagnostic one. It can either be derived from nature or synthesized in the laboratory. So it may also be an autograft (so the lipofilling), allograft or xenograft used as a transplant material. But, according to the definition of the American National Institute of Health, which at the moment is the internationally accepted one: "Biomaterial is a non-drug substance for inclusion in systems which augment or replace the function of bodily tissues or organs". The aim of the lipofilling is precisely to fill a hollow or create a volume using the patient's fat. So we can consider that lipofilling is an answer to the last definition and is a biomaterial.

Eleven articles were analyzed to assess the effectiveness of the different filling techniques for the TMF donor site. We identified 6 different BMs in this indication. It can be noted that in the literature, the two BMs that were most often used for this indication are PE and PMMA (4 studies each).

Review outcome

Efficacy

All the articles showed good results in terms of patient satisfaction. There is no difference in terms of satisfaction between different BMs. However, in the article by Baj et al., only the satisfaction of the surgeons was evaluated. We believe that patient satisfaction is the most important criteria to judge the efficacy of an aesthetic filling treatment.

Unfortunately, most articles rate patient satisfaction subjectively, without any details on how this was assessed. Finally, only 3 articles use a quantitative satisfaction scale (Cheung, 1994; Cervelli, 2014; and Mandlik, 2015). In addition, only Mandlik (Mandlik, 2015) evaluates satisfaction reliably with a validated questionnaire and imagery.

Safety

PMMA has more complications than PE and other BMs. In fact, of the 6 complications in this study, 5 were found in studies using PMMA (one for Mersilene Mesh), or 4.9% of the patients. (Figure 2)

In terms of complication rates, it would appear that PE and lipofilling are the safest BMs with no complications (38 and 45 patients respectively). With just a case report, no conclusion can be drawn concerning Titanium. On the other hand, PMMA (4.9%) and MM (10%) seem to cause more complications (Figure 2).

Nevertheless, there is a lack of completeness in the research of complications. For example, as the Cervelli et al. study shows, there are specific complications with lipofilling such as secondary interventions (multiple procedures) due to lack of results after the first procedure. Of the 45 patients in their study, 35 underwent a second procedure and one a third procedure

to achieve the expected result. A loss of results is also systematic with lipofilling, which is defined by the rate of fat resorption. For Cervelli et al. (Cervelli, 2014), resorption averaged 20.57cc after the first procedure. It is probably this high resorption rate (which ranges from 20 to 80% in some articles (Tiryaki et al., 2011)) that makes many surgeons doubt the use of lipofilling in first line treatment. This is why new methods are being used today in an attempt to reduce this loss of efficacy and to improve lipofilling, for instance by using stem cells in the recent technique of cell-assisted lipotransfer (Laloze, 2017). There are also other complications in lipofilling not identified by Cervelli, such as false cysts, abscesses, infections, oily necrosis, etc. (Zhou, 2015).

Limitations

There are many ways to fill temporal muscle donor site defects. A review of the literature already listed all the articles on the subject. They mainly concerned the prevention of this defect (Vaca, 2017). However, it seemed more relevant to focus on the effectiveness of techniques to treat temporal depression because this defect is constant. We excluded the articles that did not have sufficient data on this specific matter.

We also excluded articles about filling defects in the temporal region by the same BM which did not concern the same indication (Persing, 1994; Scholz, 2007; Gordon and Yaremchuk, 2011), but rather defects induced by craniotomy or craniectomy, and therefore related to bone and not muscle. Characteristics of the BM and the expected results were actually not comparable.

Furthermore, no data about intervention time was found. It is preferable to carry out the shortest possible procedures to reduce morbidity and mortality. It is therefore essential to collect this specific data in order to be able to compare different BMs for surgical procedures.

One of the main indications for temporal muscle flaps is oncological maxillectomies. A good portion of these patients undergo adjuvant radiotherapy, which can lead to complications ending in the loss of BM. Five of the 11 studies presented in our review analyze the effect of radiation after the introduction of a BM. With regard to PE, 2 studies discuss the effect of radiation. No complications are found in these studies, nor is there any difference in the shape of the implant after adjuvant RT. For PMMA, mersilene mesh and lipofilling, there is also a study that presents such results. No complications are found here either. Cervelli claims that there is no additional fat resorption for lipofilling. In fact, many studies demonstrate the efficacy of lipofilling after RT (van Turnhout, 2017). Lipofilling provides post-burn tissue with quality and flexibility. Finally, Mandlik demonstrates that there is no change in the shape and volume of the implant after radiation.

Nowadays, public health and its effects in terms of costs are increasingly important topics.

Health systems tend to choose the least expensive biomaterial. Lipofilling with autologous fat is the least expensive option. A PE or PMMA prosthesis costs about \$300 (“Anophthalmic Orbital Implants” n.d.; Morales-Gómez, 2018). Titanium implants cost about \$3,000 (Höhne, 2013). If we compare the average price of the 4 most frequently used BMs, lipofilling seems to be the least expensive (although several procedures may be necessary before the desired result is obtained).

In the end, the main bias of this review remains that all of the articles that were included in the

study have a low power and a low level of evidence. It is essential to perform comparative, randomized, high power studies to draw concrete conclusions.

Conclusion

Lipofilling appears to be one of the best therapeutic choices to fill the donor site after a temporal muscle flap. In fact, it is an autologous transplant, of similar consistency, with an excellent price-effectiveness ratio, few complications, and it is possible after radiotherapy. But according to the findings of this review, we cannot identify the ideal biomaterial to repair this soft tissue hollowing. Only a meta-analysis with randomized high-power studies would provide a concrete answer to the question.

Conflict of interest

This research received no specific grant from funding agencies in the public, commercial, or non-profit sectors.

References

Adenis J. Pathologie orbito-palpébrale. MASSON. PARIS; 830p p. 1998.

“Anophthalmic Orbital Implants.” n.d. Medscape. Accessed July 9,
<http://www.medscape.com/viewarticle/522302>. 2018.

Atherton, Duncan Donald, Naresh Joshi, and Niall Kirkpatrick. “Augmentation of Temporal Fossa Hollowing with Mersilene Mesh.” *Journal of Plastic Reconstructive and Aesthetic Surgery* 63 (10): 1629–34. 2010. <https://doi.org/10.1016/j.bjps.2009.09.022>.

Baj, A., S. Spotti, S. Marelli, G. A. Beltramini, and A. B. Gianni. “Use of Porous Polyethylene for Correcting Defects of Temporal Region Following Transposition of Temporalis Myofascial Flap.” *Acta Otorhinolaryngologica Italica: Organo Ufficiale Della Societa Italiana Di Otorinolaringologia E Chirurgia Cervico-Facciale* 29 (5): 265–69. 2009.

Bradley, P., and J. Brockbank. “The Temporalis Muscle Flap in Oral Reconstruction. A Cadaveric,

Animal and Clinical Study.” *Journal of Maxillofacial Surgery* 9 (3): 139–45. 1981.

Cervelli, Daniele, Giulio Gasparini, Francesca Grussu, Alessandro Moro, Tito Matteo Marianetti, Enrico Foresta, Camillo Azzuni, and Sandro Pelo. “Autologous Fat Transplantation for the Temporalis Muscle Flap Donor Site: Our Experience with 45 Cases.” *Head & Neck* 36 (9): 1296–1304. 2014. <https://doi.org/10.1002/hed.23457>.

Cheung, L. K., N. Samman, and H. Tideman. “The Use of Mouldable Acrylic for Restoration of the Temporalis Flap Donor Site.” *Journal of Cranio-Maxillo-Facial Surgery:*

Official Publication of the European Association for Cranio-Maxillo-Facial Surgery 22 (6): 335–41. 1994.

Colmenero, C., V. Martorell, B. Colmenero, and I. Sierra. “Temporalis Myofascial Flap for Maxillofacial Reconstruction.” *Journal of Oral and Maxillofacial Surgery: Official Journal of the American Association of Oral and Maxillofacial Surgeons* 49 (10): 1067–73. 1991.

Demas, P. N., and G. C. Sotereanos. “Transmaxillary Temporalis Transfer for Reconstruction of a Large Palatal Defect: Report of a Case.” *Journal of Oral and Maxillofacial Surgery: Official Journal of the American Association of Oral and Maxillofacial Surgeons* 47 (2): 197–202. 1989.

Falconer, D. T., and J. G. Phillips. “Reconstruction of the Defect at the Donor Site of the Temporalis Muscle Flap.” *The British Journal of Oral & Maxillofacial Surgery* 29 (1): 16–18. 1991.

Gola R, Laurent-Fyon C, Waller PY. [Repair of orbital exenteration cavities]. *Ann Chir Plast Esthet.*; 34(4):353-65. 1989

Gordon, Chad R., and Michael J. Yaremchuk. “Temporal Augmentation With Methyl Methacrylate.” *Aesthetic Surgery Journal* 31 (7): 827–33. 2011.

<https://doi.org/10.1177/1090820X11417425>. Habel, G., and R. Hensher. “The Versatility of the Temporalis Muscle Flap in Reconstructive Surgery.”

The British Journal of Oral & Maxillofacial Surgery 24 (2): 96–101. 1986.

Hatamleh, Muhanad M., Jason Watson, Andrew Richmond, and Dilip Srinivasan. “A

Novel Approach to Immediate Restoration of the Cosmetic Deformity After Regional Temporalis Flap Reconstruction of a Maxillary Defect: A Case Report.” *Journal of Craniofacial Surgery* 24 (6): 2186–89. 2013. <https://doi.org/10.1097/SCS.0b013e3182a41c7f>.

Höhne, Julius, Alexander Brawanski, Holger G. Gassner, and Karl-Michael. Schebesch. “Feasibility of the Custom-Made Titanium Cranioplasty CRANIOTOP®.” *Surgical Neurology International* 4 (July). 2013. <https://doi.org/10.4103/2152-7806.114811>.

Huttenbrink, Kb. “Reconstruction of Extensive Oropharyngeal Defects with the Temporalis Muscle Flap - Our 4-Year Experience in 26 Cases.” *Laryngo-Rhino-Otologie* 68 (5): 272-.1989. Koranda, F. C., M. F. McMahon, and V. R. Jernstrom. “The Temporalis Muscle Flap for Intraoral

Reconstruction.” *Archives of Otolaryngology--Head & Neck Surgery* 113 (7): 740–43. 1987. Lacey, M., and O. Antonyshyn. “Use of Porous High-Density Polyethylene Implants in Temporal

Contour Reconstruction.” *The Journal of Craniofacial Surgery* 4 (2): 74–78. 1993.

Laloze, J., A. Varin, J. Gilhodes, N. Bertheuil, J. L. Grolleau, J. Brie, J. Usseglio, L. Sensebe, T. Filleron, and B. Chaput. “Cell-Assisted Lipotransfer: Friend or Foe in Fat Grafting? Systematic Review and Meta-Analysis.” *Journal of Tissue Engineering and Regenerative Medicine*, July. 2017. <https://doi.org/10.1002/term.2524>.

Majumdar, Arun, and Roger Bainton. “Suture of Temporalis Fascia and Muscle Flaps in Temporomandibular Joint Surgery.” *The British Journal of Oral & Maxillofacial Surgery* 42 (4): 357–59. 2004. <https://doi.org/10.1016/j.bjoms.2004.04.004>.

Mandlik, Dushyant, Karan Gupta, Daxesh Patel, Purvi Patel, Rajendra Toprani, and Kaustubh Patel. "Use of Polymethyl Methacrylate-Based Cement for Cosmetic Correction of Donor-Site Defect Following Transposition of Temporalis Myofascial Flap and Evaluation of Results after Adjuvant Radiotherapy." *Journal of Reconstructive Microsurgery* 31 (9): 668–73. 2015. <https://doi.org/10.1055/s-0035-1558988>.

Menon, N. G., J. A. Girotto, N. H. Goldberg, and R. P. Silverman. "Orbital Reconstruction after Exenteration: Use of a Transorbital Temporal Muscle Flap." *Annals of Plastic Surgery* 50 (1): 38–42. 2003. <https://doi.org/10.1097/00000637-200301000-00007>.

Morales-Gómez, Jesús A., Everardo Garcia-Estrada, Jorge E. Leos-Bortoni, Miriam Delgado-Brito, Luis E. Flores-Huerta, Adriana A. De La Cruz-Arriaga, Luis J. Torres-Díaz, and Ángel R. Martínez- Ponce de León. "Cranioplasty with a Low-Cost Customized Polymethylmethacrylate Implant Using a Desktop 3D Printer." *Journal of Neurosurgery*, June, 1–7. 2018. <https://doi.org/10.3171/2017.12.JNS172574>.

Persing, J. A., P. L. Mayer, H. M. Spinelli, L. Miller, and G. R. Criscuolo. "Prevention of 'Temporal Hollowing' after Fronto-Orbital Advancement for Craniosynostosis." *The Journal of Craniofacial Surgery* 5 (4): 271–274. 1994.

Rapidis, Alexander D., and Terry A. Day. "The Use of Temporal Polyethylene Implant after Temporalis Myofascial Flap Transposition: Clinical and Radiographic Results from Its Use in 21 Patients." *Journal of Oral and Maxillofacial Surgery: Official Journal of the American Association of Oral and Maxillofacial Surgeons* 64 (1): 12–22. 2006. <https://doi.org/10.1016/j.joms.2005.09.008>.

Scholz, Martin, Michael Wehmoeller, Jutta Lehmbruck, Kirsten Schmieder, Martin Engelhardt, Albrecht Harders, and Harald Eufinger. "Reconstruction of the Temporal Contour for Traumatic Tissue Loss Using a CAD/CAM-Prefabricated Titanium Implant-Case Report." *Journal of Cranio-Maxillofacial Surgery* 35 (8): 388–92. 2007. <https://doi.org/10.1016/j.jcms.2007.06.006>.

Shagets, F. W., W. R. Panje, and J. W. Shore. "Use of Temporalis Muscle Flaps in Complicated Defects of the Head and Face." *Archives of Otolaryngology--Head & Neck Surgery* 112 (1): 60–65. 1986. Spanio di Spilimbergo, Stefano, Paolo Nordera, Samir Mardini, Giusy Castiglione, Harvey Chim, Vittore Pinna, Massimo Brunello, Claudio Cusino, Squaquara Roberto, and Ugo Baciliero. "Pedicled Temporalis Muscle Flap for Craniofacial Reconstruction: A 35-Year Clinical Experience with 366 Flaps." *Plastic and Reconstructive Surgery* 139 (2): 468e-476e. 2017. <https://doi.org/10.1097/PRS.0000000000003011>.

Su-Gwan, K. "Treatment of Temporomandibular Joint Ankylosis with Temporalis Muscle and Fascia Flap." *International Journal of Oral and Maxillofacial Surgery* 30 (3): 189–93. 2001. <https://doi.org/10.1054/ijom.2001.0047>.

Tan, Onder, Bekir Atik, and Duygu Ergen. "Temporal Flap Variations for Craniofacial Reconstruction." *Plastic and Reconstructive Surgery* 119 (7): 152e-63e. 2007. <https://doi.org/10.1097/01.prs.0000261038.49905.b6>.

Tiryaki, Tunc, Necati Findikli, and Demir Tiryaki. "Staged Stem Cell-Enriched Tissue (SET) Injections for Soft Tissue Augmentation in Hostile Recipient Areas: A Preliminary Report." *Aesthetic Plastic Surgery* 35 (6): 965–71. 2011. <https://doi.org/10.1007/s00266-011-9716-x>.

Turnhout, Arjen A. van, Saskia Fuchs, Kristel Lisabeth-Broné, Eline J. C. Vriens-Nieuwenhuis, and Wouter B. van der Sluis. “Surgical Outcome and Cosmetic Results of Autologous Fat Grafting After Breast Conserving Surgery and Radiotherapy for Breast Cancer: A Retrospective Cohort Study of 222 Fat Grafting Sessions in 109 Patients.” *Aesthetic Plastic Surgery* 41 (6): 1334–41. 2017. <https://doi.org/10.1007/s00266-017-0946-4>.

Vaca, Elbert E., Chad A. Purnell, Arun K. Gosain, and Mohammed S. Alghoul. “Review: Postoperative Temporal Hollowing: Is There a Surgical Approach That Prevents This Complication? A Systematic Review and Anatomic Illustration.” *Journal of Plastic, Reconstructive & Aesthetic Surgery* 70 (March): 401–415. 2017. <https://doi.org/10.1016/j.bjps.2016.10.008>.

Wal, K. G. van der, and J. W. Mulder. “The Temporal Muscle Flap for Closure of Large Palatal Defects in CLP Patients.” *International Journal of Oral and Maxillofacial Surgery* 21 (1): 3–5. 1992.

Worley, C. M., and R. A. Strauss. “Augmentation of the Anterior Temporal Fossa after Temporalis Muscle Transfer.” *Oral Surgery, Oral Medicine, and Oral Pathology* 78 (2): 146–50. 1994.

Wright, S., F. Bekiroglu, N. M. Whear, and N. R. Grew. “Use of Palacos (R)-40 with Gentamicin to Reconstruct Temporal Defects after Maxillofacial Reconstructions with Temporalis Flaps.” *British Journal of Oral & Maxillofacial Surgery* 44 (6): 531–33. 2006. <https://doi.org/10.1016/j.bjoms.2005.11.014>.

Zhou, Renpeng, Chen Wang, Yunliang Qian, and Danru Wang. “Combined Flaps Based

on the Superficial Temporal Vascular System for Reconstruction of Facial Defects.” *Journal of Plastic, Reconstructive & Aesthetic Surgery: JPRAS* 68 (9): 1235–1241. 2015.

<https://doi.org/10.1016/j.bjps.2015.04.022>.

Figures

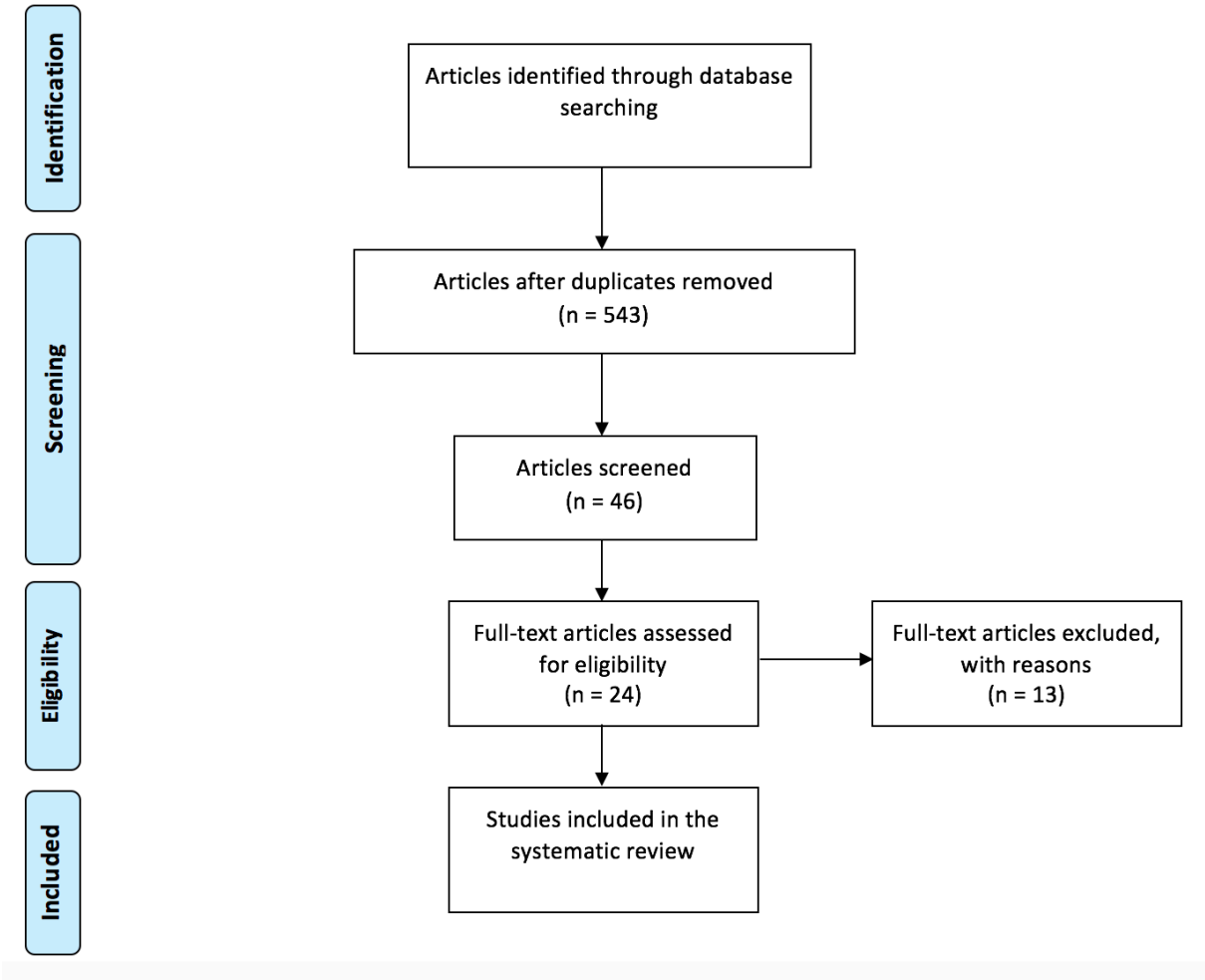


Figure 1. Flow chart of study selection

Table 1. Characteristics of the included studies

Nb	Study	Nb of patients	Age, Yr (mean+/-SD, range)	Type of biomaterial	Follow-up, Mo (mean+/-SD, range)	Satisfaction	Complications
1	Falconer et al. 1991	2	74	Acrylic prosthesis	7,5	good result	NA
2	Lacey et al. 1993	4	34	Polyethylene	24-48	Good result	0
3	Cheung et al. 1994	34	50 (7-85)	Acrylic cement	24,5	26 excellent result, 6 satisfactory result, 2 poor result	2 persistent hollowing with 1 re-intervention 21 months after the first one
4	Worley et al. 1994	1	30	Polyethylene	6	Patient quite satisfied	0
5	Wright et al. 2005	41	NA	Acrylic cement	132	acceptable results	1 infection --> removal of the implant
6	Rapidis et al. 2006	21	66,2+/-16,7 (32-85)	Polyethylene	38,9+/-21,1 (9-70)	very good or excellent from the patient	0
7	Atherton et al. 2010	10 (but 13 temporal defect)	40,1+/-12,5 (25-56)	Mersilene mesh	15,9+/-11,7 (7-38)	pleasing outcomes to both patient and surgeon	1 infection
8	Baj et al. 2009	12	60 (36-84)	Polyethylene	(12-36)	satisfactory by the surgeons	0
9	Cervelli et al. 2013	45	52,8	Lipofilling	22	fully satisfactory 86,6%; satisfactory 11,1%; unsatisfactory 2,2%; 16,9/20 at photographic scale	NA; only the resorption rate after procedure : 20,57cc for the first, 7,94cc for the second and 3cc for the third
10	Hatamleh et al. 2013	1	54	Titanium	NA	Good result from the patient	0
11	Mandlik et al. 2015	25	59,1+/-10,6 (39-78)	PMMA	80,4+/-13 (61-108)	Questionnaire and CT Scan, good results	2 (1 seroma and 1 wound dehiscence)

Yr : Year; SD : Standard Deviation; Mo : Month; NA : Not Available;
PMMA : PolyMethylMethAcrylate

Table 2. Study design and level of evidence

Nb	Study	Nb of patients	Study design	Level of evidence
1	Falconer et al. 1991	2	Retrospective case series	IV
2	Lacey et al. 1993	4	Retrospective case series	IV
3	Cheung et al. 1994	34	Retrospective case series	IV
4	Worley et al. 1994	1	Case report	IV
5	Wright et al. 2005	41	Retrospective case series	IV
6	Rapidis et al. 2006	21	Retrospective case series	IV
7	Atherton et al. 2010	10 (but 13 temporal defect)	Retrospective case series	IV
8	Baj et al. 2009	12	Retrospective case series	IV
9	Cervelli et al. 2013	45	Prospective case series	III
10	Hatamleh et al. 2013	1	Case report	IV
11	Mandlik et al. 2015	25	Prospective case series	IV

Study design and level of evidence based on Oxford Center for Evidence-Based Medicine 2011 guidelines (Howick J, Chalmers I, Glasziou P, et al. *The Oxford 2011 Levels of Evidence*, Oxford Center for Evidence-Based Medicine, Available at: <http://www.cebm.net/index.aspx?o=5653>. Accessed September 21, 2014).

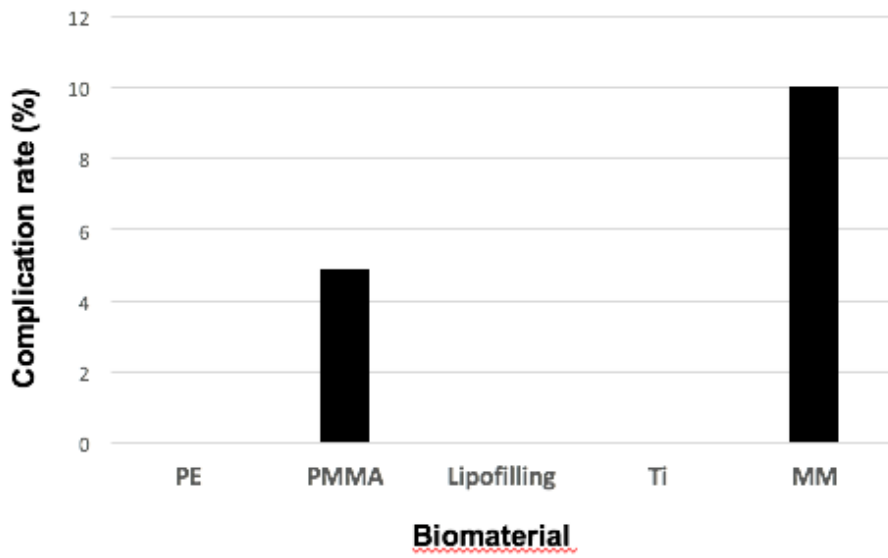


Figure 2. Complication rate of different biomaterial in percentage.