



HAL
open science

Lower-limb Flip-Flap: A simple reliable modification of adipofascial flap for extensive tibial crest cutaneous defect

Jérémy Hardy, Alexandra Forli, Jean-Louis Charissoux, Christian Mabit,
Pierre Sylvain Marcheix

► To cite this version:

Jérémy Hardy, Alexandra Forli, Jean-Louis Charissoux, Christian Mabit, Pierre Sylvain Marcheix. Lower-limb Flip-Flap: A simple reliable modification of adipofascial flap for extensive tibial crest cutaneous defect. *Orthopaedics & Traumatology: Surgery & Research*, 2020, 106 (5), pp.819-823. 10.1016/j.otsr.2020.03.026 . hal-03407060

HAL Id: hal-03407060

<https://unilim.hal.science/hal-03407060>

Submitted on 22 Aug 2022

HAL is a multi-disciplinary open access archive for the deposit and dissemination of scientific research documents, whether they are published or not. The documents may come from teaching and research institutions in France or abroad, or from public or private research centers.

L'archive ouverte pluridisciplinaire **HAL**, est destinée au dépôt et à la diffusion de documents scientifiques de niveau recherche, publiés ou non, émanant des établissements d'enseignement et de recherche français ou étrangers, des laboratoires publics ou privés.



Distributed under a Creative Commons Attribution - NonCommercial 4.0 International License

Technical note

Lower-limb Flip-Flap: a simple reliable modification of adipofascial flap for extensive tibial crest cutaneous defect.

Jérémy **Hardy**¹, Alexandra **Forli**², Jean-Louis **Charissoux**¹, Christian **Mabit**¹, Pierre Sylvain **Marcheix**¹

1 Service de Chirurgie Orthopédique, CHU de Limoges, Centre Hospitalier Universitaire de Limoges, Limoges, France

2 Unité de Chirurgie Plastique des Membres, de la Main et des Brûlés, CHU Grenoble, Centre Hospitalier Universitaire Grenoble Alpes Hôpital Sud, Grenoble, France

Corresponding Author: Jérémy Hardy, M.D.
Limoges University Hospital Center,
Orthopedics
2 avenue Martin Luther King
87000 Limoges, France
geremyhardy@wanadoo.fr

ABSTRACT

INTRODUCTION: Large cutaneous defects exposing the whole tibial crest are difficult to cover and are conventionally best treated with free flaps. This article describes a technical modification of the adipofascial flap in this indication.

METHODS: The “flip-flap” is vascularized by the posterior tibial artery perforators harvested on the medial aspect of the leg. The hypodermal and fascial tissue is de-epidermized and elevated from the posterior midline up to the medial edge of the soleus muscle, then folded over the exposed tibial crest like a page of a book.

RESULTS: A 27x6 cm defect was successfully covered on a 72 year-old patient with vascular status precluding free flap. The flap healed by day 21.

DISCUSSION/CONCLUSION: This technical modification is simple and allows coverage of large tibial crest skin defect when a free flap is not possible.

Keywords: Adipofascial flap; Perforator flap; Tibia; Lower limb; Defect

INTRODUCTION:

Covering extensive tibial crest skin defect (here, >80% of the anteromedial side of the tibial shaft) is a challenge for which the optimal surgical solution is not established.

Cover classically uses free flaps [1], for which a specialized surgeon is necessary and failure rates even so can be as high as 31% [2]. Moreover, receiver site vascularization has to be of good quality [3], which is not always the case.

Techniques have therefore been developed using combined local flaps: soleus + reverse sural [4], or gastrocnemius + hemisoleus [5,6]. Results are often impaired, however, by traumatizing a limb already harboring multi-tissue lesions [7].

Adipofascial flap harvested from the anteromedial side of the limb was developed by Heymans, with excellent results in defects from knee to foot [8-11].

We describe "flip-flap", a modified adipofascial flap that is easy to perform to cover extensive tibial crest skin defect.

We describe the anatomic bases underlying its reliability and the modification, illustrated with clinical data.

METHODS

ANATOMIC BASES

The Flip-Flap is an adipofascial flap vascularized by the posterior tibial artery perforators.

It is harvested from the subcutaneous and fascial tissue vascularized by the posterior tibial artery perforators. This territory extends over the medial side of the limb: proximal-to-distal, from 5 cm below the inferior end of the patella to the apex of the medial malleolus, and anteroposteriorly from the tibial crest to the line between the two heads of the gastrocnemius [12] (Figure 1). Dissection should not exceed this territory.

The septocutaneous perforators vascularizing the flap lie between the flexor digitorum longus body and the soleus muscle [13] and/or between the tibia and the flexor digitorum longus [14]. The musculocutaneous perforators mainly lie on the medial edge of the soleus [12,13] (Figure 1).

The flap is thus vascularized by a mean 6 (3 to 9) posterior tibial artery perforators [14]. A flap raised on just one perforator is viable [15] – and the Flip-Flap all the more.

SURGICAL TECHNIQUE:

Preoperative stage (Figure 2)

The perforators are located by Doppler (*Minidop 100VX, 8MHz; Hadeco*) on a 2 cm strip behind the medial edge of the tibial shaft (where most septocutaneous perforators emerge [13,14]). The flap contours are traced on the medial side of the limb tangentially to the superior and inferior defect edges up to the midline posteriorly.

Dissection: Adipofascial flap exposure step (Figure 3).

After resection of the unstable tibial crest skin and infected part of the tibia and intramedullary curettage, flap dissection begins with extensive strictly subdermal release exposing the hypodermis over the whole flap surface, following the preoperative plan. Release thus does not damage the suprafascial vessels and thus does not jeopardize flap viability.

Dissection: Flap elevation (Figure 4).

The flap is sectioned posteriorly along the midline, and superiorly and inferiorly tangentially to the defect. It is sectioned down to the fascia, included in the flap. Subfascial release continues from posterior to anterior to the medial relief of the soleus muscle, stopping there so as to avoid injury to the septocutaneous perforators between soleus and

flexor digitorum longus. No perforator dissection is needed. The saphenous vein is sacrificed on flap elevation.

Dissection: Flap adjustment (Figure 5)

The adipofascial flap is folded over to cover the tibia and skin defect, like the page of a book, with the adipose side against the exposed bone and the fascial side outward; A "counter-flap" is dissected by 1 cm hypodermal release of the lateral edge of the defect, and the adipofascial flap is brought over the deep side of the release zone and fixed by absorbable subcutaneous suture.

By dissecting the Flip-Flap starting from the posterior midline, lateral migration overlaps the lateral edge of the tibia by 1-2 cm.

The dermal and epidermal tissue dissected during flap exposure is repositioned on the muscles of the posterior compartment as a dermo-epidermal graft, secured by a compress.

PRINCEPS CASE REPORT

A 72 year-old man had sustained an open tibial shaft fracture 30 years previously, treated by external fixator and Papineau technique [16], achieving consolidation.

Clinical examination found fragile cutaneous scar tissue with multiple fistulae at the anteromedial side of the tibia over an area of 27x 6 cm. Scintigraphy with labeled leukocytes and multi-level biopsy found osteomyelitis with bone sequestrs along 22 cm of the mid-third of the shaft.

Curettage and saucerization was performed on the anteromedial side of the tibia and 3 months' antibiotic therapy was initiated. The unstable skin was unviable intraoperatively.

Free flap reconstruction was contraindicated by preoperative CT angiography findings of a single permeable posterior tibial axis and grade 2 lower-limb arteriopathy obliterans.

RESULTS

At 21 days, the flap was completely healed, with no necrosis in the dermo-epidermal tissue over the posterior compartment muscles.

For the exposed part of the flap, a dermo-epidermal graft was successfully performed at 1 month.

At 13 months' follow-up (Figure 6), there was no recurrence of bone sepsis, either clinically (pain, fistula), radiologically (labeled leukocyte fixation on scintigraphy, sequester on CT), or biologically (CRP and leukocyte count).

DISCUSSION

Flip-Flap is a modification of Heymans' adipofascial flap [8], covering extensive pretibial skin defect over more than 80% of the anteromedial side of the tibia when a free flap is precluded by local conditions.

The major difference in dissection technique is in the flap hinge. For Heymans, the hinge is transverse, with anterograde or retrograde pediculation on the posterior tibial artery perforators. For Flip-Flap, it is longitudinal, with pediculation on all posterior tibial artery perforators on a longitudinal line along the septum between the flexor digitorum longus and soleus muscles.

In the present case, receiver-site skin graft was postponed to 1 month; it can, however, perfectly well be performed immediately.

The technique is quick and simple, as no vascular dissection is involved if flap elevation stops before reaching the medial edge of the soleus, thus respecting all septocutaneous perforators.

There are, however, some drawbacks. Adipofascial flaps have a lower capacity for in-situ antibiotic delivery than muscle flaps [17]. Even so, studies increasingly report comparable sepsis control between adipofascial and muscular flaps [11]. Using Flip-Flap for shorter defects may not be indicated, as it could not be sure whether a perforator was included. Preoperative Doppler could check perforator location. If there are none adjacent to the defect, some other kind of local flap seems preferable. The large dermo-epidermal tissue repositioned on the muscles of the posterior compartment, being no longer vascularized by the hypodermis, is liable to necrosis, although this did not occur in the present case: the tissue was doubtless revascularized by imbibition, like a total skin graft [18,19]

CONCLUSION

Flip-Flap is a simple and reliable technique for covering extensive tibial crest skin defect.

Conflicts of interest:the authors have no Conflict of Interest

Sources of funding:none

Authors' contribution: all authors contributed actively to this work

REFERENCES

1. Engel H, Lin CH, Wei FC. Role of microsurgery in lower extremity reconstruction. *Plast Reconstr Surg* 2011;127:228S–238S
2. Pu LLQ, Medalie DA, Rosenblum WJ, Lawrence SJ, Vasconez HC. Free tissue transfer to a difficult wound of the lower extremity. *Ann Plast Surg* 2004;53:222–228.
3. Shipkov H, Traikova N, Voinov P, Boucher F, Braye F, Mojallal A. Vascular loops in reconstructive microsurgery: A review of the literature. *Ann Chir Plast Esth.* 2014;59:1–8.
4. Hassanpour SE, Yavari M, Motabar AR. Synchronous Soleus and Reverse Sural Flap for Large Soft Tissue Defect Reconstruction of Leg. *World J Plast Surg.* 2018 Jan;7(1):12-15.
5. Thornton BP, Pu LLQ. Reconstruction of an extensive tibial soft tissue defect with multiple local muscle flaps for limb salvage when free tissue transfer was not an option. *Euro J Plast Surg* 2004;27:217-21.
6. Hyodo I, Nakayama B, Takahashi M, Toriyama K, Kamei Y, Torii S: The gastrocnemius with soleus bi-muscle flap. *Br J Plast Surg*2004; 57: 77-82.
7. Salibian AH, Menick FJ. Bipedicle gastrocnemius musculocutaneous flap for defects of the distal one-third of the leg. *Plast Reconstr Surg.* 1982;70:17–23.
8. Heymans O, Peters S, VanZele D, Gielen J.L, Fissette J. Les lambeaux adiposofasciaux de la face antéro-interne de jambe : une alternative aux lambeaux libres pour la couverture des pertes de substance cutanée du genou au talon. À propos d'une expérience clinique de 17 cas. *Ann Chir Plast Esth* 2001; 46 : 629-36
9. Heymans O, Verhelle N, Peters S, Nélisten X, Oelbrandt B. Use of the medial adipofascial flap of the leg for coverage of full-thickness burns exposing the tibial crest. *Burns* 2002; 28 :674–678
10. Heymans O, Verhelle N, Peters S. The Medial Adiposofascial Flap of the Leg: Anatomical Basis and Clinical Applications. *Plast. Reconstr. Surg.* 2005;115: 793
11. Verhelle N, Vranckx J, Van den Hof B, Heymans O. Bone Exposure in the Leg: Is a Free Muscle Flap Mandatory? *last. Reconstr. Surg.* 2005;116: 170
12. Tang M, Mao Y, Almutairi K, Morris SF. Three-dimensional analysis of perforators of the posterior leg. *Plast Reconstr Surg* 2009;123:1729-1738
13. Ozdemir R, Kocer U, Sahin B, et al. Examination of the skin perforators of the posterior tibial artery on the leg and the ankle region and their clinical use. *Plast Reconstr Surg* 2006;117:1619-1630.
14. Whetzel TP, Barnard MA, Stokes RB. Arterial fasciocutaneous vascular territories of the lower leg. *Plast Reconstr Surg* 1997;100:1172-1183.

15. Hung, L. K., Lao, J., and Ho, P. C. Free posterior tibial perforator flap: Anatomy and a report of 6 cases. *Microsurgery* 17: 503, 1996.
16. Papineau LJ. Excision-graft with deliberately delayed closing in chronic osteomyelitis. *Nouv Presse Med.* 1973;2:2753–2755.
17. Gosain, A., Chang, N., Mathes, S., Hunt, T. K., and Vasconez, L. A study of the relationship between blood flow and bacterial inoculation in musculocutaneous and fasciocutaneous flaps. *Plast. Reconstr. Surg.* 86: 1152, 1990.
18. Converse JM, Uhlschmid GK, Ballantyne DL Jr. “Plasmatic circulation” in skin grafts. The phase of serum imbibition. *Plast Reconstr Surg* 1969;43:495–9.
19. Capla JM, Ceradini DJ, Tepper OM, et al. Skin graft vascularization involves precisely regulated regression and replacement of endothelial cells through both angiogenesis and vasculogenesis. *Plast Reconstr Surg* 2006;117:836–44.

FIGURE LEGENDS

Figure 1:

Anatomic bases of Flip-Flap. Left: multilevel anatomic anteromedial cross-section along the tibial shaft, with emergence of musculocutaneous and septocutaneous perforators. Box: Territory vascularized by posterior tibial artery perforators.

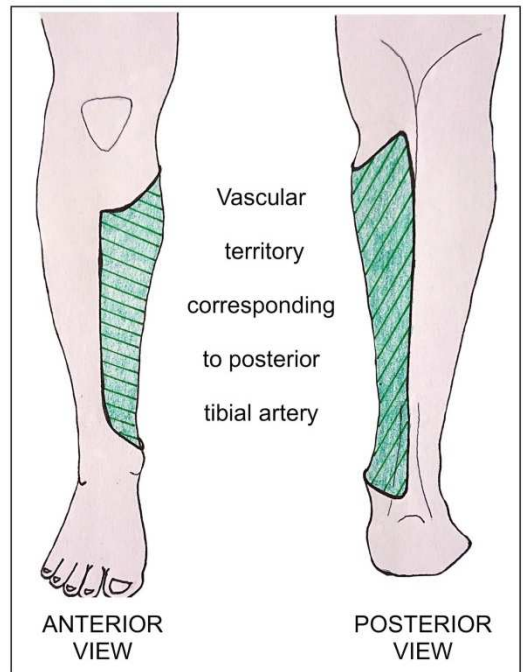
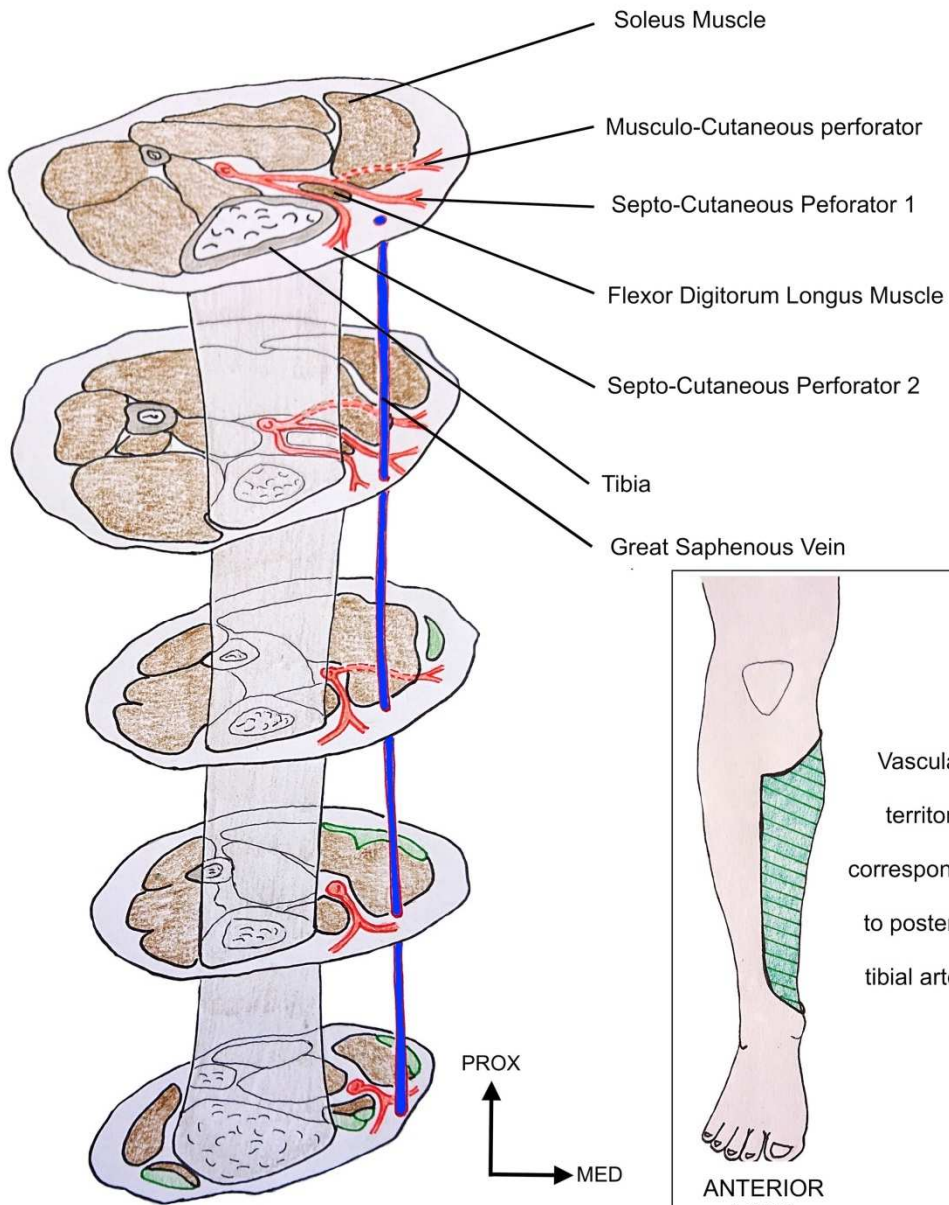
Figure 2: Surgical technique, preoperative phase. Top: photograph of princeps case. Bottom: explanatory “transparency” diagram of underlying anatomic structures.

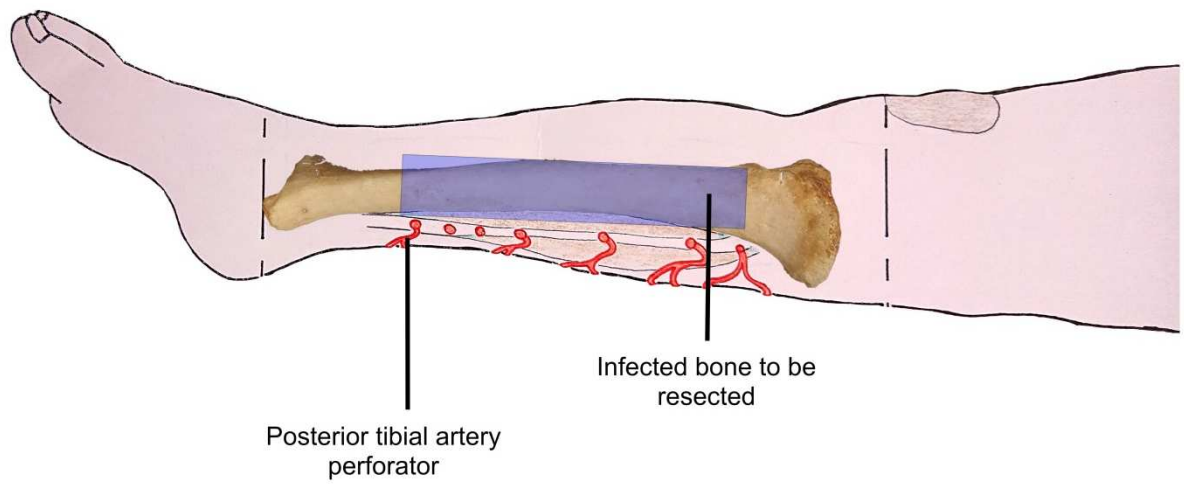
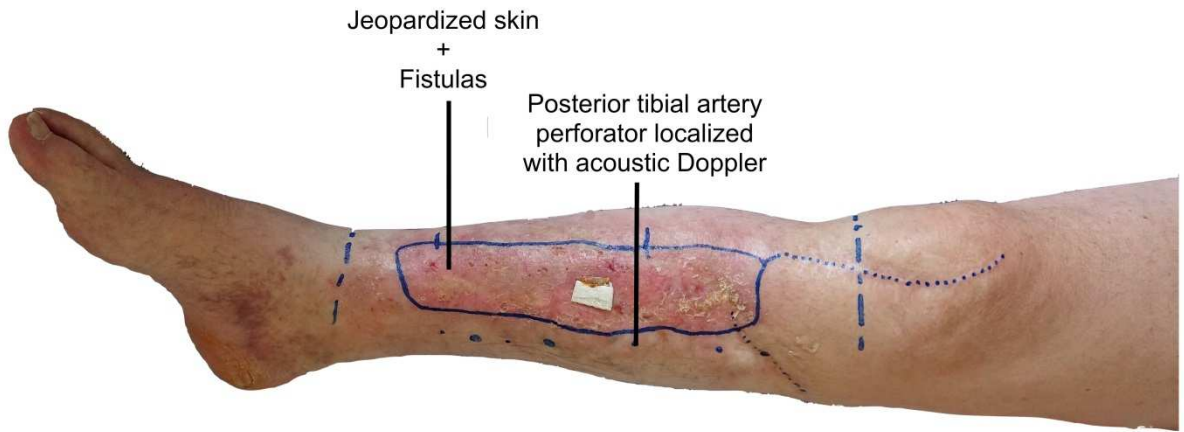
Figure 3: Surgical technique, flap exposure phase. Top: intraoperative photograph. Bottom: explanatory “transparency” diagram; posterior tibial artery perforators and subcutaneous distribution.

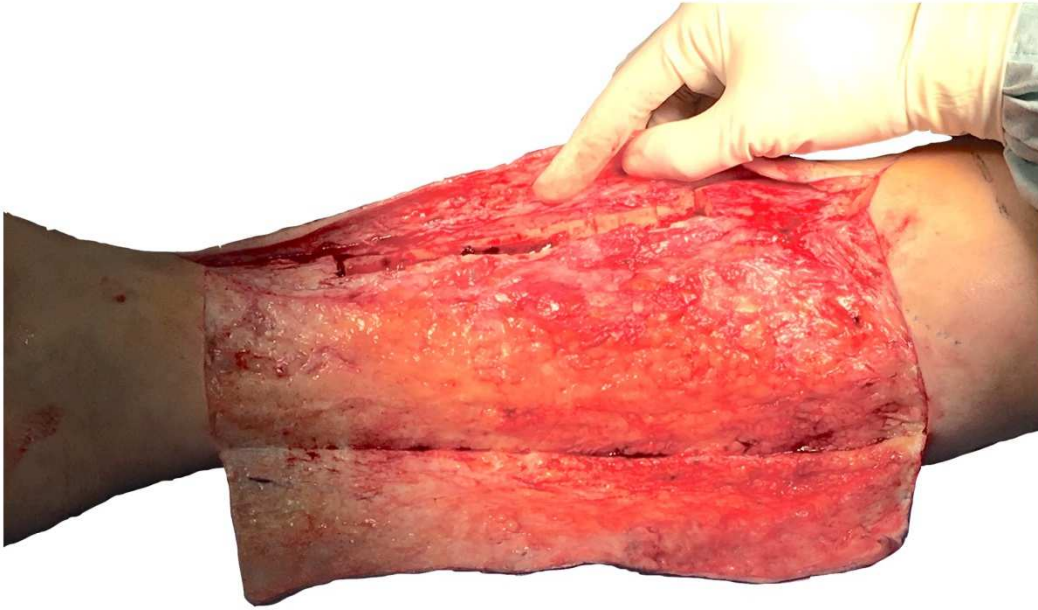Figure 4: Surgical technique, flap elevation phase. Top: intraoperative photograph. Bottom: explanatory “transparency” diagram.

Figure 5: Surgical technique, flap adjustment phase. Left: intraoperative photograph. Box: cross-sectional view of flap in position.

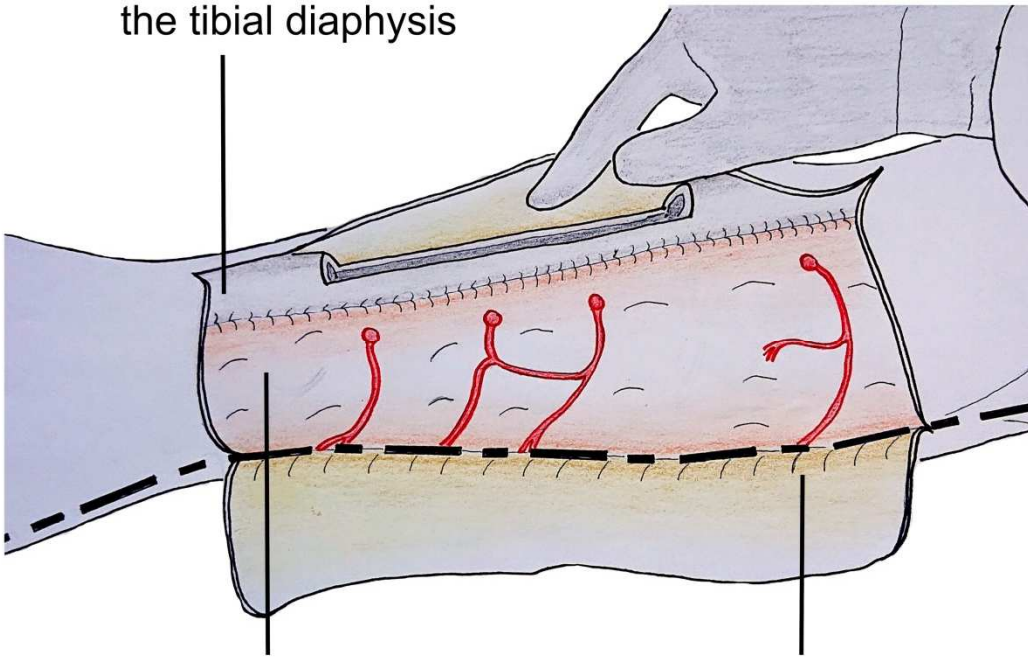
Figure 6: Clinical aspect at 13 months, with dermo-epidermal graft on previously exposed part of the flap.





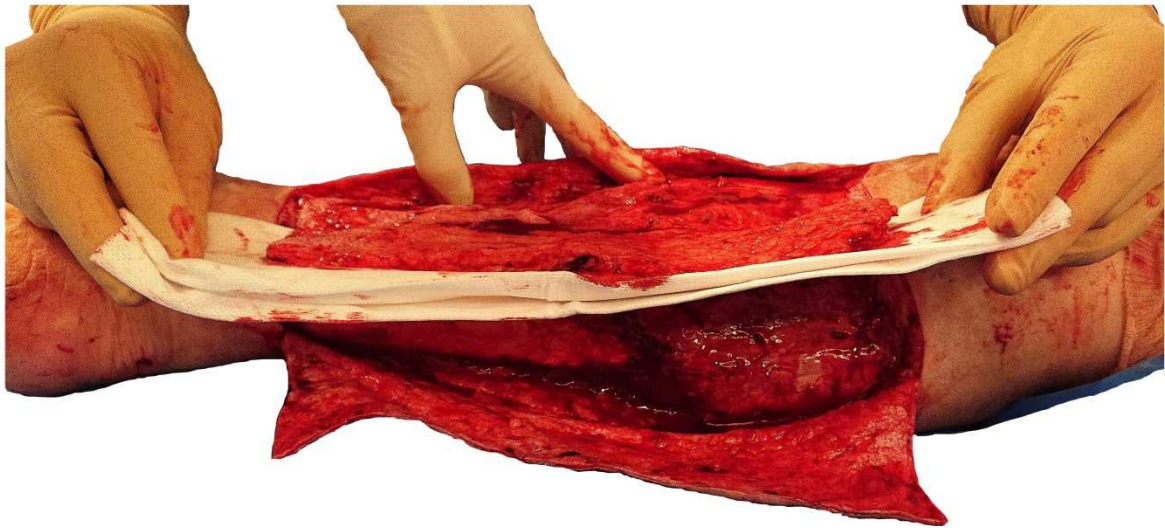


Infected bone resected from the tibial diaphysis



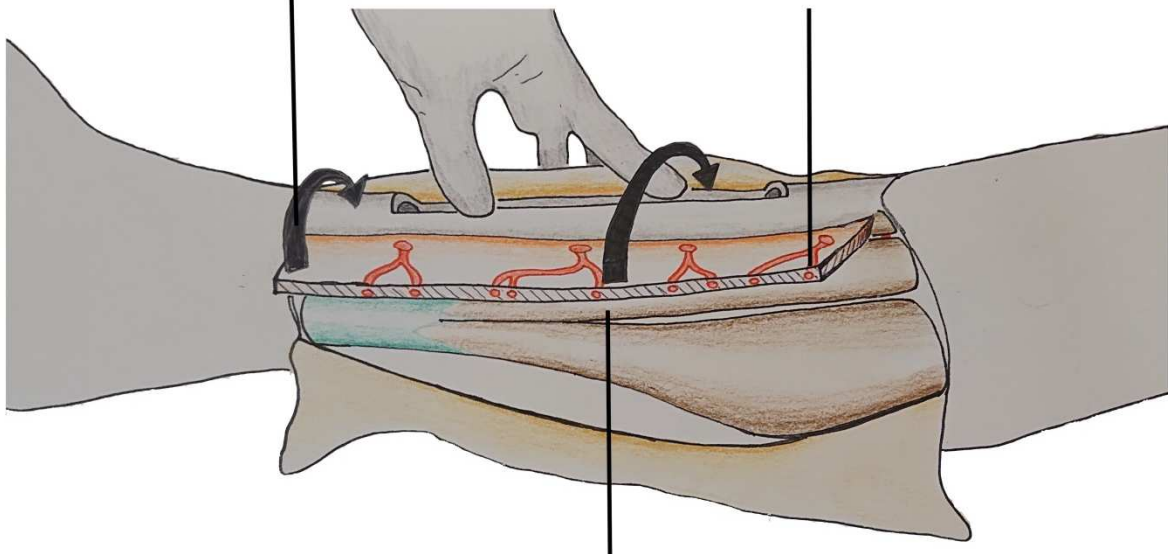
Exposed hypodermis
+
Subcutaneous distribution of
posterior tibial artery
perforators

Epidermis + dermis
dissected up to the
posterior median line



Adipofascial flap harvested
+
distribution of posterior tibial
artery perforators within the
flap

The flap is folded
over the tibial crest



The flap is elevated
from the subfascial plane
Dissection stops
at the level of the medial border of the soleus

