



HAL
open science

The human costal cartilage: Anatomical and radiological study of macro-vascularization and micro-vascularization and its clinical relevance regarding vascularized chondrocostal free flap surgery

Jérémy Hardy, Sacha Chrosciany, Jean-Philippe Bernard, Christian Mabit,
Pierre-Sylvain Marcheix

► To cite this version:

Jérémy Hardy, Sacha Chrosciany, Jean-Philippe Bernard, Christian Mabit, Pierre-Sylvain Marcheix. The human costal cartilage: Anatomical and radiological study of macro-vascularization and micro-vascularization and its clinical relevance regarding vascularized chondrocostal free flap surgery. *Annals of Anatomy*, 2020, 232, pp.151581. <10.1016/j.aanat.2020.151581>. <hal-03407371>

HAL Id: hal-03407371

<https://unilim.hal.science/hal-03407371v1>

Submitted on 22 Aug 2022

HAL is a multi-disciplinary open access archive for the deposit and dissemination of scientific research documents, whether they are published or not. The documents may come from teaching and research institutions in France or abroad, or from public or private research centers.

L'archive ouverte pluridisciplinaire HAL, est destinée au dépôt et à la diffusion de documents scientifiques de niveau recherche, publiés ou non, émanant des établissements d'enseignement et de recherche français ou étrangers, des laboratoires publics ou privés.



Distributed under a Creative Commons CC BY-NC 4.0 - Attribution - Non-commercial use - International License

Title: The Human costal cartilage: anatomical and radiological study of macro-vascularization and micro-vascularization and its clinical relevance regarding vascularized chondrocostal free flap surgery.

Authors: Jérémy Hardy, MD - Sacha Chrosciany, MD - Jean-Philippe Bernard, MD - Christian Mabit, MD-PhD - Pierre-Sylvain Marcheix, MD, PhD.

Affiliation of the Authors:

Department of Orthopedic Surgery, Dupuytren University Hospital. 2, Avenue Martin Luther King, 87042 LIMOGES cedex.

Correspondence to: Dr.Pierre-Sylvain Marcheix,Department of Orthopedic Surgery, Dupuytren University Hospital. 2, Avenue Martin Luther King, 87042 LIMOGES cedex.

E-Mail: psmarcheix@orange.fr

Short title: The costal cartilage vascularization

Key words: Chondrocostal, Cartilage defect, Morphology, Vascularization, Pedicular graft, Anatomy

JH, SC, JPB, CM, PSM: No conflict of interest

Funding: No funding required for this study.

Author contributions: JH, SC, PSM - study development, article writing. CM -article proofreading.

Abstract (words: 276)

Introduction: Cartilage repair usually involves in non-vascularized osteochondral or chondral grafts with some drawbacks potentially linked to the lack of vascular supply in those grafts. The aim of this study was to describe a surgical approach for harvesting a vascularized chondrocostal graft, to study the vascular supply to the perichondrium and finally to describe the perichondrium microvascularization in order to know how such grafts could be used in cartilage repair surgery.

Materials and methods: We harvested and studied eighteen costal cartilages harvested from 12 fresh anatomical subjects. The anatomic pieces were injected with a radio-opaque tracer, analyzed macroscopically, then a plain X-rays and CT scan analysis with three-dimensional rendering was performed in order to evaluate the characteristics of the different patterns of their vascularization.

Results: the surgical approach to harvest a vascularized 5th chondrocostal graft is explained in detail. All of the cartilages were vascularized by the internal thoracic artery **and harvested with a pedicle of** an average length of 34mm and diameter of 2.14mm. In all specimens, perichondrium vascularization arises from both superior and inferior intercostal branches. Anastomoses between inferior and superior intercostal branches are always found in all specimens at the level of the epichondrium.

Conclusions:

The anatomic approach for harvesting a vascularized chondrocostal graft is simple and only slightly differs from the approach described for harvesting a non-vascularized chondrocostal graft. The vascular supply to the perichondrium of such a vascularized chondrocostal graft is sustained by the internal thoracic vessels which have a sufficient diameter and length to allow easy micro-anastomosis. The organization of the microvasculature within the perichondrium allows the graft to be tailored to a large cartilage defects and also to small bipolar cartilage defects.

1. Introduction

Dealing with cartilage damage or loss is a challenge in reconstructive surgery. Many surgeons have advocated the use of free [non vascularized](#) costal cartilage grafts to deal with post traumatic articular cartilage loss of small dimensioned joints such as the [radio carpal joint with both distal radius](#) (Furukawa et al., 2014; Obert et al., 2011; Obert et al., 2015; Tropet et al., 2006) and scaphoid [cartilage defects](#) (Tropet et al., 2006).

Nevertheless, [the use of such non vascularized grafts](#) is mainly limited by cartilage resorption (Binger and Hell, 1999; De et al., 2010; Tjelmeland and Stal, 2000) and bony metaplasia (Obert et al., 2015) with loss of [their](#) anatomic function. Some authors found that cartilage progenitor cells found in the deep layer of the perichondrium could account for cartilage regeneration (Borst, 1909; Gao et al., 2019; Mollon et al., 2013; Tuan et al., 2013; Wang et al., 2013). Tjelmeland et al. showed that a chondrocostal graft implanted with its perichondrium in an ectopic location better sustained cartilage resorption compared to bare costal cartilage (Tjelmeland and Stal, 2000). Obert et al. and Sato et al. found that maintaining a vascular supply to the perichondrium could lower the risk of bony metaplasia of the cartilaginous part of a [chondrocostal](#) graft (Obert et al., 2013; Sato et al., 2008). The use of vascularized chondrocostal grafts in articular cartilage restoration could thereby limit the drawbacks of non-vascularized grafts. There were, to our knowledge, no anatomical studies on how to harvest a free vascularized chondrocostal flap and no anatomical studies on how the perichondrium is finely vascularized.

The aims of this study were to:

- Describe a [surgical](#) approach for harvesting a vascularized chondrocostal graft.
- Describe the vascular supply to the perichondrium for future use in free vascularized chondrocostal flap (microsurgical anastomoses).
- Describe the dimensions of the harvested grafts
- Describe the microvascularization within the perichondrium to know how this flap could be tailored to the cartilage surface loss.

2. Materials and methods

2.1 Dissection

This study was based on 18 osteochondrocostal grafts harvested from 12 fresh anatomical subjects (6 men and 6 women from the Limoges body donation program) kept at + 4 ° C. The harvesting technique was similar to the techniques already described for non-vascularized grafts (Lepage et al., 2016; Loisel et al., 2018). The specificities for harvesting a vascularized chondrocostal graft were exposed in the « Results » section.

2.2 Conditioning of the anatomic pieces

In order to assess the microvascularisation within the perichondrium, the anatomical pieces including bone and cartilage were conditioned by arterial injection. All the costal cartilages were injected with liquid epoxy resin (type R123 and R614, Soloplast Vosschemie), carmine red pigment and barium sulfate (Azelis France). The anatomical pieces were then dried and kept cool (between 3 and 5°C) for 48 hours to allow the epoxy compound to polymerize. After drying, in order to avoid radiological artifacts, the costal cartilages were soaked to decalcify in a solution of Rapid Bone Decalcifier (Osteomoll, VMR) for 6 hours.

2.3 Imaging analysis

All the anatomic pieces were then processed with the following sequence:

- Standard X-rays imaging (anteroposterior and cranio-caudal views) then CT-scan imaging (Imation Philips 64-bar CT-Scan, sections 1/1, 3 millimeters).
- CT-scan acquisitions were processed to get a 3D rendering using AW software (GE Healthcare).

3. Results

3.1 Description of the Anatomical approach for harvesting a vascularized chondrocostal graft (Fig 1)

A horizontal skin incision was performed on the osteochondral junction of the fifth rib, centered on the medio-clavicular line (Fig 1a). The costal cartilage was superficially exposed splitting the pectoralis major muscle fibers. Dissection carried on the upper and the lower border of the rib close to the lateral border of the sternum. The superior and inferior intercostal branches were found and protected by keeping a cuff of intercostal muscle. The superior and inferior intercostal branches were then followed up to their origin at the internal thoracic pedicle (Fig 1b). The intercostal arteries were then ligated and a chondrocostal osteotomy was performed (Fig 1c). This osteotomy allowed to gain access to the posterior border of the costal cartilage, helping to visualize the internal thoracic artery and vein, which were then freed from the sternal periosteum (Fig 1d). The harvested specimens included the chondrocostal perichondrium, the endothoracic fascia of the parietal pleura remained in place. The internal thoracic artery and vein could be harvested on a longer portion by performing an adjacent rib osteotomy thus elongating the pedicle of the graft (Fig 1e).

3.2: Description of the vascular supply to the perichondrium (Table 1)

Arterial injections of the internal thoracic artery resulted in:

- both radiologic and macroscopic opacification of the vascular network at the level of the perichondrium in all the 18 specimens.
- saline solution outflow at the level of the internal thoracic vein.

The perichondrium was therefore vascularized by branches emerging from the internal thoracic artery and vein. The average length of the dissected internal thoracic artery and vein was 37mm (24-55mm). The length of the internal thoracic artery and vein could be elongated up to 82 mm when an adjacent rib was elevated.

All the costal cartilages included one artery with an average diameter of 2.1mm (1.6-2.3mm) and one vein with an average diameter of 2.5mm (2.1-2.7mm).

3.3 Description of the dimensions of the vascularized chondrocostal graft (Table 2)

The average dimensions of the anatomical pieces were 45mm in length, 24mm in width and 12mm in thickness, with a cartilaginous portion of an average length of 16mm.

3.4 Description of the micro-vascularization within the perichondrium:

Macroscopic analysis:

After injection, the perichondrium microvasculature was macroscopically visible on the anterior aspect of the chondrocostal grafts in 16 out of 18 cartilages samples (89%) and on the posterior aspect of 15 out of 18 of the chondrocostal grafts (83%).

Plain X-Ray (Fig. 2) and CT (Fig. 3) analysis:

After injection the plain X-Ray and CT scan analysis showed that the perichondrium micro-vascularization arised both from superior and inferior intercostal branches in all specimens (18/18). The superior and inferior intercostal branches anastomosed at the level of the epichondrium micro-vascularization in all specimens (18/18). X-ray imaging suggested that both the anterior and the posterior perichondrium were richly vascularized. This is confirmed by CT scan analysis: both the anterior and the posterior part of the perichondrium were richly vascularized in 16 out of 18 cases (89%). In 2 out of 18 cases (11%) CT-Scan was unable to find any posterior perichondrium vascularization.

Moreover in 4 of 18 cases (22%) CT scans found that perichondrium micro-vascularization directly arose from the internal thoracic artery. CT scan analysis also suggested that no artery significantly penetrated the undersurface of the cartilage, all the vasculature seemed to be only in the perichondrium.

4. Discussion

This study shows that the surgical approach for harvesting a vascularized chondrocostal graft is simple and only slightly differs from the approach described for harvesting a non-vascularized chondrocostal graft. A key feature of this approach remains in the opportunity to elongate the vascular pedicle to the graft (internal thoracic pedicle) by osteotomizing an adjacent rib. The vascular supply to the perichondrium of such a vascularized chondrocostal graft is sustained by the internal thoracic vessels which have a minimal diameter above 1,5 mm and a minimal length of 24 mm (which could be extended up to 82 mm when an adjacent rib osteotomy is performed). Finally, the organization of the microvasculature within the perichondrium suggests that constant anastomosis exist between the superior and inferior intercostal branches. This organization also suggests that the perichondrium is richly vascularized by the branches of the intercostal vessels [which constantly arise from](#) the internal thoracic vessels.

This study could be considered as a preliminary study for a vascularized chondrocostal free flap pedicled on the internal thoracic vessels. The harvesting technique is standardized and reliable and rather safe if one respects the underlying tissues (pleura etc...). Furthermore the length of the pedicle (up to 82 mm), and the diameter of the internal thoracic vessels (more than 1,5 mm) allow to perform easy microsurgical anastomoses at a remote site (Ohtani et al., 2001). Due to the rich anastomotic network at the level of the perichondrium, the costal cartilage flap could be modular to fit various cartilage defects. For instance, a vertical split could allow bipolar cartilage resurfacing of small joints, and a horizontal split could allow monopolar resurfacing of large and wide cartilage defects (Fig. 4).

Limitations:

- In 2 specimens out of 18, this study was unable to find any posterior perichondrium vascularization. This could be worrisome when those grafts should be used for an « horizontal split » leading to a half of the cartilage surface with no vascular supply. A study with more specimen should be performed in order to know whether this vascular anatomic variation is frequent or scarce.
- This study only focused on how such a vascularized graft could be harvested and tailored to the donor site. There is actually no effective evidence that such vascularized grafts could better sustain cartilage resorption and/or bony metaplasia: experimental studies are compulsory to investigate those hypotheses.

External validity:

Our findings about the characteristics of the internal thoracic artery were consistent with the work of Gopal et al. and Ohtani et al. who found that the diameter of the internal thoracic vessels was above 2 mm (Gopal et al., 2013; Ohtani et al., 2001). The vascular supply to the chondrocostal cartilage was also studied by several authors (Henriquez-Pino et al., 1997; Pogrel et al., 1997) and all of these studies confirmed our findings of an anterior chondrocostal part of the rib vascularized by the internal thoracic artery via the intercostal branches and perichondrium. However, we were unable to find any studies about the organization of the microvascularization within the perichondrium. Another option to increase survival of the free vascularized chondrocostal flap should be to use of Platelet Rich Plasma within the recipient site as advocated by Sönmez et al. (Sonmez et al., 2013).

5. Conclusion

Chondrocostal cartilage is vascularized through the perichondrium by intercostal branches arising from the internal thoracic pedicle. The perichondrium is the support of micro-anastomoses from the superior and inferior intercostal branches. Those vasculature patterns could allow the use of a free vascularized chondrocostal flap in various indications for reconstructive surgery.

6. Acknowledgements:

The authors wish to sincerely thank those who donated their bodies to science so that anatomical research could be performed. Results from such research can potentially improve patient care and increase mankind's overall knowledge. Therefore, these donors and their families deserve our highest gratitude.

7. REFERENCES

- Binger, T., Hell, B., 1999. Resorption of microsurgically vascularized bone grafts after augmentation of the mandible. *J Craniomaxillofac Surg* 27, 82-85.
- Borst, M., 1909. *Das pathologische wachstum: organisation, regeneration and verwandte gewebbildungen.* Jena, Gustav Fischer, Aschoff L.
- De, L.G., Fricain, J., Stoll, D., 2010. Resorption of cartilage grafts in rhinoplasty: fundamental basis. *Revue de laryngologie-otologie-rhinologie* 131, 83-88.
- Furukawa, K., Sakai, A., Menuki, K., Oshige, T., Zenke, Y., Nakamura, T., 2014. Post-traumatic malunion of the distal radial intra-articular fractures treated with autologous costal osteochondral grafts and bioabsorbable plates. *Tech Hand Up Extrem Surg* 18, 15-19.
- Gao, Y., Gao, J., Li, H., Du, D., Jin, D., Zheng, M., Zhang, C., 2019. Autologous costal chondral transplantation and costa-derived chondrocyte implantation: emerging surgical techniques. *Ther Adv Musculoskelet Dis* 11, 1759720X19877131.
- Gopal, D., Singh, N.G., Jagadeesh, A.M., Ture, A., Thimmarayappa, A., 2013. Comparison of left internal mammary artery diameter before and after left stellate ganglion block. *Ann Card Anaesth* 16, 238-242.
- Henriquez-Pino, J.A., Gomes, W.J., Prates, J.C., Buffolo, E., 1997. Surgical anatomy of the internal thoracic artery. *Ann Thorac Surg* 64, 1041-1045.
- Lepage, D., Tatu, L., Loisel, F., Rey, P.B., Obert, L., Parratte, B., 2016. Anatomical and computed tomography study of the eighth costochondral junction: topography for costochondral graft harvesting. *Surg Radiol Anat* 38, 809-815.
- Loisel, F., Pluvy, I., Kielwasser, H., Panouilleres, M., Obert, L., Lepage, D., 2018. Technical note on the harvesting of rib osteochondral autografts for upper limb bone and joint repair surgery. *Hand surgery and rehabilitation* 37, 337-341.
- Mollon, B., Kandel, R., Chahal, J., Theodoropoulos, J., 2013. The clinical status of cartilage tissue regeneration in humans. *Osteoarthritis Cartilage* 21, 1824-1833.
- Obert, L., Lepage, D., Ferrier, M., Tropet, Y., 2013. Rib cartilage graft for posttraumatic or degenerative arthritis at wrist level: 10-year results. *J Wrist Surg* 2, 234-238.
- Obert, L., Lepage, D., Sergent, P., Rochet, S., Gallinet, D., Tropet, Y., Garbuio, P., 2011. Post-traumatic malunion of the distal radius treated with autologous costal cartilage graft: a technical note on seven cases. *Orthop Traumatol Surg Res* 97, 430-437.

Obert, L., Loisel, F., Gindraux, F., Tropet, Y., Lepage, D., 2015. Rib cartilage grafting in upper limb surgery: an overview. *SICOT J* 1, 13.

Ohtani, N., Kiyokawa, K., Asada, H., Kawakami, T., Haga, M., Akasaka, N., 2001. Evaluation of an internal thoracic artery as a coronary artery bypass graft by intercostal duplex scanning ultrasonography. *Jpn J Thorac Cardiovasc Surg* 49, 343-346.

Pogrel, M.A., Podlesh, S., Anthony, J.P., Alexander, J., 1997. A comparison of vascularized and nonvascularized bone grafts for reconstruction of mandibular continuity defects. *J Oral Maxillofac Surg* 55, 1200-1206.

Sato, K., Sasaki, T., Nakamura, T., Toyama, Y., Ikegami, H., 2008. Clinical outcome and histologic findings of costal osteochondral grafts for cartilage defects in finger joints. *J Hand Surg Am* 33, 511-515.

Sonmez, T.T., Vinogradov, A., Zor, F., Kweider, N., Lippross, S., Liehn, E.A., Naziroglu, M., Holzle, F., Wruck, C., Pufe, T., Tohidnezhad, M., 2013. The effect of platelet rich plasma on angiogenesis in ischemic flaps in VEGFR2-luc mice. *Biomaterials* 34, 2674-2682.

Tjelmeland, K., Stal, S., 2000. Cartilage graft resorption: an animal model. *Aesthetic Surgery Journal* 20, 471-476.

Tropet, Y., Lepage, D., Gallinet, D., Obert, L., Garbuio, P., Vichard, P., 2006. [Articular reconstructions by a costochondral grafting (or osteochondral costal grafting)]. *Bull Acad Natl Med* 190, 1439-1456; discussion 1456-1437, 1475-1437.

Tuan, R.S., Chen, A.F., Klatt, B.A., 2013. Cartilage regeneration. *The Journal of the American Academy of Orthopaedic Surgeons* 21, 303.

Wang, Y., Wei, L., Zeng, L., He, D., Wei, X., 2013. Nutrition and degeneration of articular cartilage. *Knee Surg Sports Traumatol Arthrosc* 21, 1751-1762.

Tables and Figures:

Figure 1: Surgical approach for harvesting a vascularized chondrocostal graft:

1a: Incision at the level of the 5th rib centered on the medio-clavicular line.

1b: Exposure of the 5th rib with internal thoracic vessels dissected.

1c: Ligature of the intercostal arteries and veins and osteotomy of the rib.

1d: Flap elevation keeping the internal thoracic vessels intact at the underneath surface of the flap and finger dissection avoiding damage to the parietal pleura.

1e: Technique for flap pedicle elongation using the 6th rib osteotomy.

Table 1: Characteristics of the vascular supply to the perichondrium of the harvested grafts.

Table 2: Dimensions of the harvested grafts

Figure 2: X-Ray aspect of an injected costal cartilage specimen before and after suppression of background noise. Upper: anteroposterior view, lower: cranio-caudal view.

Figure 3: CT Scan aspect of injected costal cartilage specimen after three-dimensional reconstruction. Upper: superior view, middle: anterior view, lower: lateral view.

Figure 4: Schematic representation of the vascularized chondrocostal free flap modularity. Upper: different types of split, Middle: after a « vertical split », lower: after an « horizontal split ».

Figure 1: Anatomical approach for harvesting a vascularized chondrocostal graft:

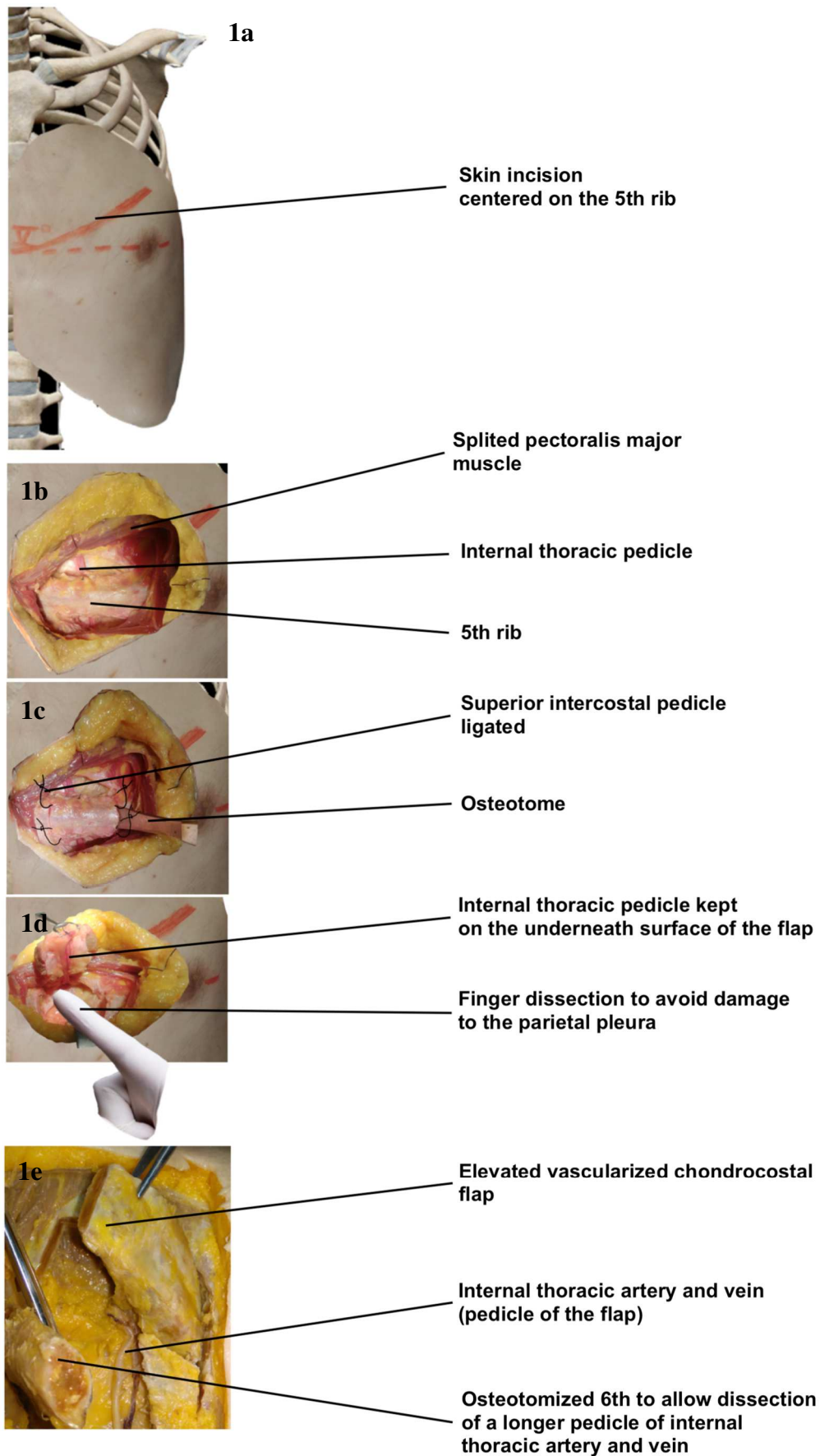


Table 1: Characteristics of the vascular supply to the perichondrium of the harvested grafts.

	Minimal (mm)	Maximal (mm)	Mean (mm)
Length of the vascular pedicle	24	55	37
Diameter of the artery	1.6	2.3	2.1
Diameter of the vein	2.1	2.7	2.5

Table 2: Dimensions of the harvested grafts.

	Minimal (mm)	Maximal (mm)	Mean (mm)
Width	36	54	45
Thickness	21	31	24
Length of the cartilaginous part	10	18	12

Figure 2: X-Ray aspect of an injected costal cartilage specimen before and after suppression of background noise.

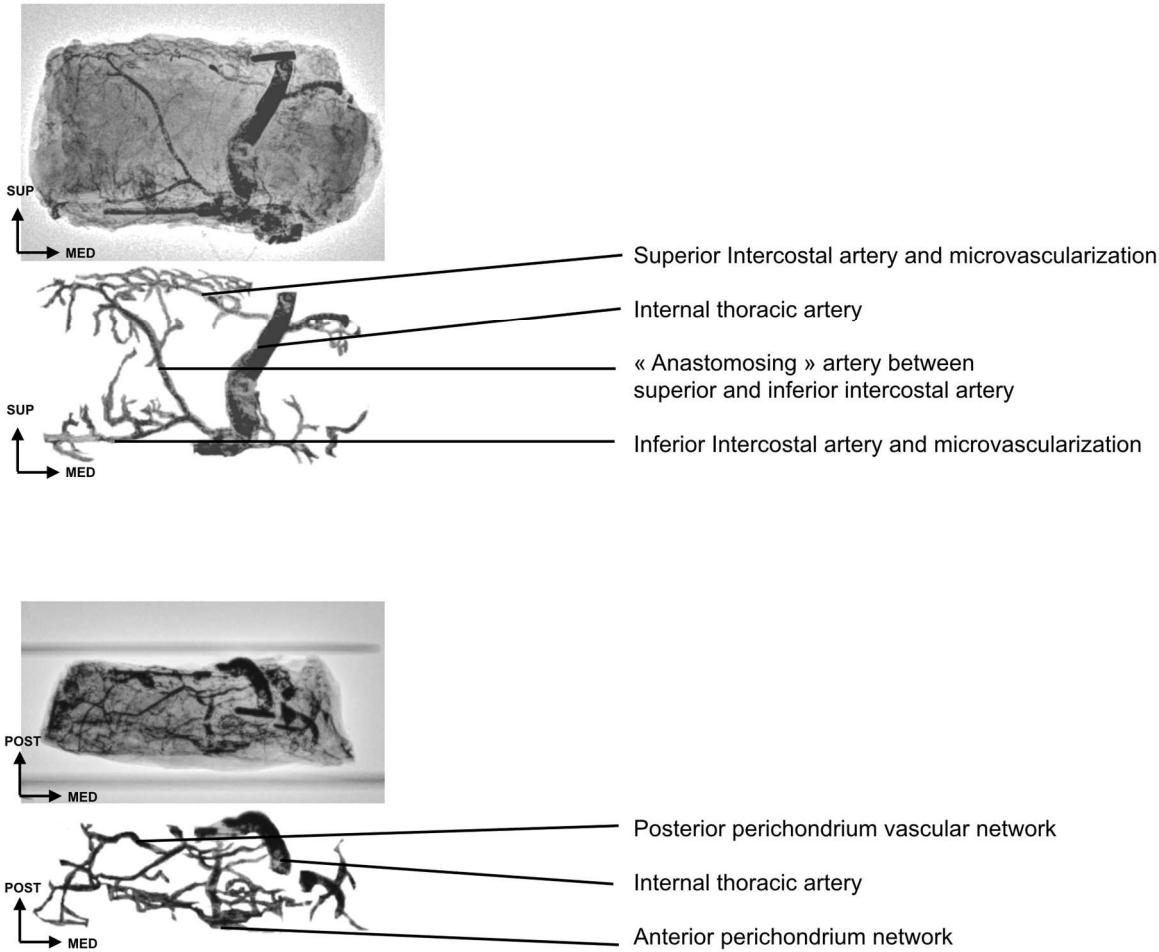
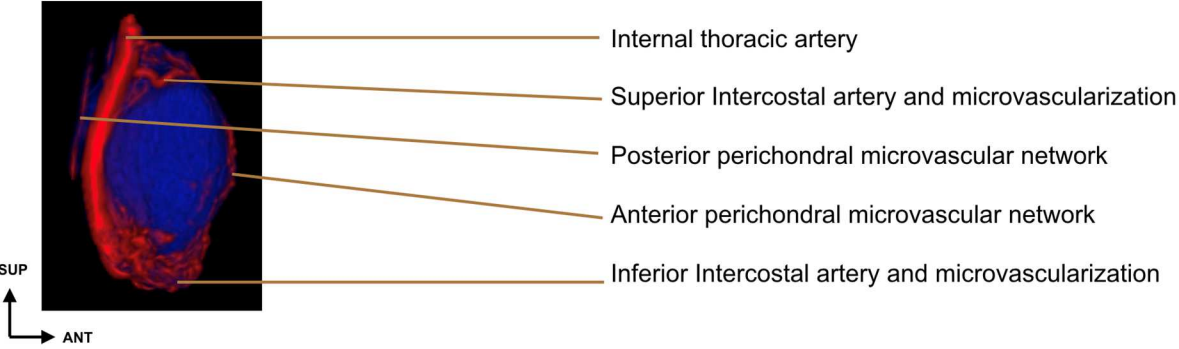
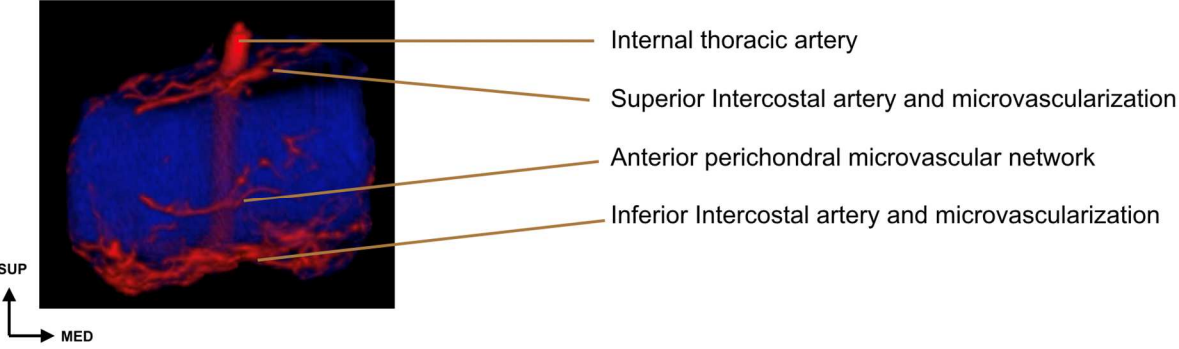
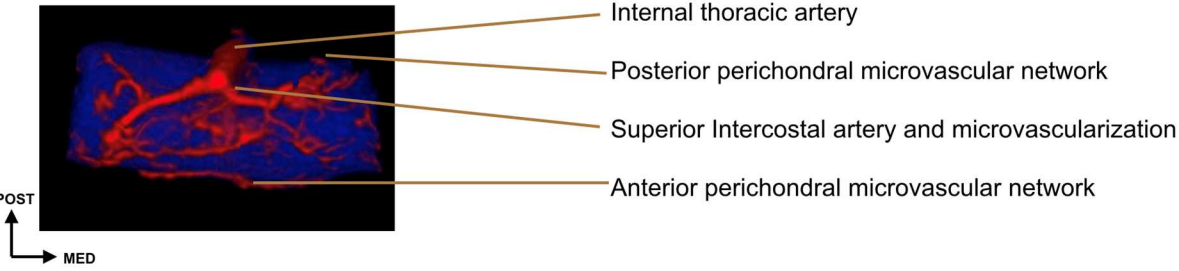


Figure 3: CT Scan aspect of injected costal cartilage specimen after three-dimensional reconstruc-



tion:

Figure 4: Schematic representation of the vascularized chondrocostal free flap modularity.

